

鼻咽部 Warthin 瘤 1 例报道并文献复习

朱杭军¹, 刘洋君², 刘赞¹

(1. 南京中医药大学无锡附属医院 耳鼻咽喉科, 江苏 无锡 214000; 2. 中国人民解放军联勤保障部队第 904 医院 耳鼻咽喉科, 江苏 无锡 214044)

摘要: **目的** 总结 1 例鼻咽部 Warthin 瘤并后鼻孔闭锁患者的临床资料, 并结合相关文献进行复习, 探讨鼻咽部 Warthin 瘤的可能来源, 以加深对此类疾病的了解。**方法** 对收治的 1 例后鼻孔闭锁患者行鼻内镜下双侧后鼻孔粘连松解+后鼻孔成形术, 术中见右侧后鼻孔完全闭锁, 左侧鼻腔后鼻孔狭窄。以电刀自鼻中隔处打开左侧后鼻孔, 继而向外侧切除后鼻孔增生组织, 松解左侧后鼻孔粘连, 扩大后鼻孔, 同法行右侧手术。术后组织送病检。**结果** 术中双侧后鼻孔开放满意, 术后患者症状消失。送检组织并病理提示为微小 Warthin 瘤。随访 1 年肿瘤无复发。**结论** 头颈部 Warthin 瘤多见于涎腺, 尤以腮腺居多。发生于鼻咽部的极为罕见, 通常认为其来源于鼻咽部散在小涎腺或者黏膜上皮化生, 鼻内镜下手术切除为安全有效治疗手段。

关键词: 鼻内镜手术; 鼻咽部; 咽鼓管; Warthin 瘤

中图分类号: R766.3

Warthin's tumor of the nasopharynx: a case report and literature review

ZHU Hangjun¹, LIU Yangjun², LIU Yun¹

(1. Department of Otolaryngology, Wuxi Affiliated Hospital of Nanjing University of Traditional Chinese Medicine, Wuxi 214000, China; 2. Department of Otolaryngology, the 904th Hospital of Joint Logistic Support Force of PLA, Wuxi 214044, China)

Abstract: **Objective** To report a case of nasopharyngeal adenomatous lymphoma complicated with posterior nostril atresia, review the relevant literature, try to explore its possible source, and deepen the understanding of the diagnosis and treatment of the rare disease. **Methods** One patient with bilateral posterior nostril atresia was treated with transnasal endoscopic choanal plasty for repairing choanal atresia. During surgery, it was discovered that the the right posterior nostril was completely atresia and the left posterior nostril was narrowed. The left posterior nostril atresia was opened from the nasal septum by electric knife, removed it to the lateral side, expand posterior nostril. The same procedure was performed on the right side. The tissues were sent to the department of pathology for diagnosis. **Results** The bilateral posterior nostril was treated satisfactorily and the symptoms disappeared. Histological examination suggested for Warthin tumor. There was no recurrence during 1 year follow-up. **Conclusion** Warthin tumor of head and neck is mainly found in salivary gland, especially parotid gland. Warthin tumor is extremely rare in the nasopharynx. It is generally believed to originate from the small salivary glands scattered in the nasopharynx or mucosal metaplasia. Nasal endoscopic resection is a safe and effective treatment.

Keywords: Endoscopic nasal surgery; Nasopharynx; Eustachian tube; Warthin tumor

Warthin 瘤又称腺淋巴瘤或淋巴乳头状囊腺瘤, Hilderbrand 于 1895 年首次将这种肿瘤描述为一种先天性颈部囊肿, 1929 年 Warthin 将这种肿瘤称为乳头状囊腺瘤淋巴瘤^[1]。多发于涎腺, 尤以腮腺常见, 发生于鼻咽部极少, 南京中医药大学无锡附属医院于 2017 年 6 月收治 1 例女性鼻咽部 Warthin 瘤并后鼻孔闭锁患者, 尤为罕见, 检索文献, 现有鼻咽部

Warthin 瘤资料均为零散个案报道, 对其发生于鼻咽部的可能因素尚无明确定论, 本文整理相关资料, 并对其来源作初步探讨。

1 临床资料

患者, 女, 73 岁, 10 年前感冒后出现双侧鼻塞、

第一作者简介: 朱杭军, 男, 硕士, 主任医师。Email: zhuhj2008@126.com

流脓涕,右侧为重。当地医院保守治疗无效,遂行右侧鼻腔、鼻窦手术(手术方式不详),术后仍时有交替性鼻塞,右侧明显,伴有脓涕,近2年症状明显加重,右侧持续鼻塞多脓涕,于2017年6月来院就诊,以鼻腔粘连、右侧后鼻孔闭锁收治入院。入院查体:双侧鼻腔见较多脓涕分泌物,清理后见右侧鼻腔后外侧壁向内侧膨隆,与鼻中隔黏膜粘连,后鼻孔完全闭锁。专科检查左侧鼻腔后鼻孔狭窄(图1、2)。CT检查显示鼻窦鼻咽右侧隆起,向内与鼻中隔粘连,后鼻孔完全闭锁,左侧后鼻孔狭窄(图3)。实验室检查无异常。于全麻鼻内镜下行双侧后鼻孔粘连松解+后鼻孔成形术,术中见右侧后鼻孔完全闭锁,以电刀自鼻中隔处打开后鼻孔,继而向外侧切除后鼻孔增生组织,松解左侧后鼻孔粘连,扩大后鼻孔,双侧鼻腔膨胀海绵填塞。术后病理结果提示右侧后鼻孔送检组织为微小淋巴乳头状囊腺瘤(图4)。1周后出院,术后9、12个月复查无复发,后患者未再复诊。

2 讨论

2.1 流行病学

Warthin 瘤为唾液腺良性肿瘤,其发病有逐年增加趋势,90%以上均发生于腮腺,大多数数据表明其为腮腺良性肿瘤第二位,占腮腺肿瘤的5%~6%,其发病和吸烟密切相关,男性高于女性^[2-5],Kadletz等^[6]还指出 Warthin 瘤发病率增加和代谢综合征之间可能存在联系,尤其是和肥胖有密切关系,也有欧洲学者研究证明 Warthin 瘤近年超越多形性腺瘤成为首位腮腺良性肿瘤^[7]。我国学者对3724例唾液腺肿瘤分析表明,99%以上的唾液腺 Warthin 瘤发生于腮腺,男女比例约为4:1,好发年龄为40~70岁,且近10年有明显增加趋势^[8],对华东地区1084例 Warthin 瘤的回顾性研究表明男女发病比例为11:1,多灶性 Warthin 瘤的发生率为9.5%,其中28例发生在腮腺外部位,没有1例位于鼻咽部,由此可见鼻

咽部 Warthin 瘤相当罕见^[9]。检索文献,从1989年至今共有13例鼻咽部 Warthin 瘤报道(含本例),发病年龄52~81岁,男9例,女4例(2.25:1),其中3例男性患者有明确大量吸烟史,5例患者同时合并腮腺腺淋巴瘤(38.5%)^[10-21]。

2.2 肿瘤来源

鼻咽部 Warthin 瘤来源尚无一致意见,有人认为是起源于鼻咽部小的散发的唾液腺,也有认为来源于上皮化生^[10,12-15]。近来 Valstar 等^[22]通过 PET-CT 发现在咽鼓管隆凸区域分布人体另一较大唾液腺,并称之为隆凸唾液腺,分析放疗引起的鼻咽部干燥不适可能同该腺体受到照射有关。现有报道的鼻咽部 Warthin 瘤除3例位于鼻咽顶部外,其余10例均位于鼻咽侧壁,假设隆凸唾液腺确实存在(因为该腺体是否存在仍有争议^[23])根据 Warthin 瘤好发于唾液腺的特点,加之大多数鼻咽部 Warthin 瘤位于鼻咽侧壁,我们推测鼻咽部侧壁的 Warthin 瘤是否与隆凸唾液腺有关,或者就是发生于隆凸唾液腺的肿瘤?因为隆凸唾液腺为新提出的概念,其最终仍需要更多病例研究证实,如果术前能考虑到隆凸唾液腺可能,术中又能做到扩大切除,病理证实肿瘤位于腺体内,应该具有一定说服力。发生于顶壁的则可能和小的散发的唾液腺有关。

2.3 临床表现

本组数据中,患者首次就诊分别表现为无症状5例(体检发现)^[15-19],表现为分泌性中耳炎4例^[13-14,20-21],鼻塞、后鼻孔狭窄(闭锁)2例^[14],头痛^[10]、鼻咽部异物感^[11]、鼻出血^[12]各1例。因鼻咽部腺淋巴瘤生长缓慢,早期多无临床症状,本组病程16个月到10年,因此过半患者为检查时发现;因其病变多位于鼻咽侧壁,对咽鼓管咽口造成压迫,故相当一部分患者出现传导性聋、耳痛、中耳积液等分泌性中耳炎表现。本例患者没有中耳炎表现。鼻咽部检查大多数病例均表现为鼻咽侧壁或者顶壁椭圆形或圆形肿物,表面黏膜光滑(9/13),有4例(含本例)仅表现为鼻咽部黏膜增厚^[14,20-21]。本病由于发

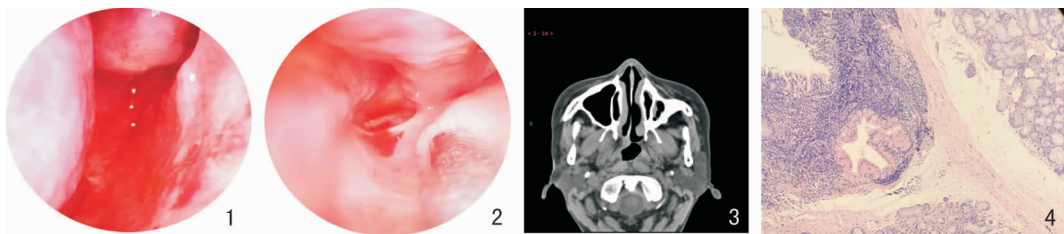


图1 右侧后鼻孔完全阻塞检查 (HE ×100)

图2 左侧后鼻孔狭窄

图3 CT示右侧后鼻孔粘连闭锁、左侧后鼻孔狭窄

图4 病理

病部位比较隐匿,且病程比较长,早期常无明显症状,因此早期发现比较困难,值得注意。

2.4 疾病诊断

据现有资料分析,该瘤生长应比较缓慢,早期无症状时很难发现。诊断可从以下几方面考虑:①临床表现:鼻咽部异物感、分泌性中耳炎表现、鼻塞、头痛等;②体检:更多依赖内镜检查,发现鼻咽部表面光滑的肿物或者鼻咽部黏膜增厚导致后鼻孔狭窄、闭锁体征,部分患者可有中耳积液体征;③影像检查:CT 或者 MRI 检查,尤其是 MRI 检查可能对疾病诊断更有价值。遗憾的是本例患者由于我们对该病认识不足,没有做 MRI 检查,导致资料不够完善。至于影像检查是否有特异性表现,由于相关资料不够完善,尚有待总结;④病理:最终诊断仍有赖于病理证实。本病均为发现鼻咽部肿物或鼻咽黏膜增生,通过术后病理确诊,在出现临床症状及检查发现鼻咽部肿物时不妨将该病考虑在内。

2.5 治疗及预后

治疗目前均以手术切除为主,在鼻内镜下基本均能很好暴露并切除病灶,本例随访 12 个月无复发,后失访,从现有资料看,术后随访时间长短不一,但均无复发报道,提示鼻咽部 Warthin 瘤手术切除预后较好。

参考文献:

- [1] Kuzenko YV, Romanuk AM, Dyachenko OO, et al. Pathogenesis of Warthin's tumors[J]. *Int Med Appl Sci*, 2016, 8(2): 41 – 48.
- [2] Rizzi MD, Thompson LD. Papillary cystadenoma lymphomatosum (Warthin tumor) [J]. *Ear Nose Throat J*, 2003, 82(12): 920 – 922.
- [3] Luers JC, Guntinas-Lichius O, Klusmann JP, et al. The incidence of Warthin tumours and pleomorphic adenomas in the parotid gland over a 25-year period[J]. *Clin Otolaryngol*, 2016, 41(6): 793 – 797.
- [4] Tunç O, Gönültaş B, Arslanhan Y, et al. Change in Warthin's tumor incidence: a 20-year joinpoint trend analysis[J]. *Eur Arch Otorhinolaryngol*, 2020, 277(12): 3431 – 3434.
- [5] Chloupek A, Zarzycki K, Dąbrowski J, et al. Parotid gland tumors: results of retrospective analysis of 149 patients treated at the clinical department of cranio-maxillofacial surgery, clinic of otolaryngology and oncologic laryngology of military institute of medicine in warsaw in years 2006 – 2016[J]. *Otolaryngol Pol*, 2017, 71(3): 37 – 42.
- [6] Kadletz L, Grasl S, Perisanidis C, et al. Rising incidences of Warthin's tumors may be linked to obesity: a single-institutional experience[J]. *Eur Arch Otorhinolaryngol*, 2019, 276(4): 1191 – 1196.
- [7] Psychogios G, Vlastos I, Thölken R, et al. Warthin's tumour seems to be the most common benign neoplasm of the parotid gland

- in Germany[J]. *Eur Arch Otorhinolaryngol*, 2020, 277(7): 2081 – 2084.
- [8] 吕慧欣,王卓然,高愉淇,等. 3 724 例唾液腺肿瘤的临床病理分析[J]. *中华口腔医学杂志*, 2019, 54(1): 10 – 16.
- [9] Xu W, Lu H, Zhu Y, et al. Warthin's tumour in oral and maxillofacial regions: an 18-year retrospective study of 1084 cases in an eastern-Chinese population [J]. *Int J Oral Maxillofac Surg*, 2018, 47(1): 913 – 917.
- [10] Daroszewski M, Burduk PK, Marszałek A. Endoscopic surgery for Warthin's tumor of the nasopharynx[J]. *Otolaryngol Pol*, 2012, 66(3): 232 – 235.
- [11] Kawakami M, Ito K, Tanaka H, et al. Warthin's tumor of the nasopharynx: a case report[J]. *Auris Nasus Larynx*, 2004, 31(3): 293 – 298.
- [12] Berrocal Postigo E, Galera Ruiz H, Ruiz Clemente J, et al. Ectopic Warthin's tumour in nasopharynx. Revision of one clinical case [J]. *Acta Otorrinolaringol Esp*, 2005, 56(7): 328 – 330.
- [13] Griffiths AP, Dekker P. Oncocytic metaplasia of the nasopharynx or extra-parotid Warthin's tumour? [J]. *J Clin Pathol*, 1991, 44(12): 1030 – 1032.
- [14] Kristensen S, Tveterås K, Friedmann I, et al. Nasopharyngeal Warthin's tumour: a metaplastic lesion [J]. *J Laryngol Otol*, 1989, 103(6): 616 – 619.
- [15] Hilton JM, Phillips JS, Hellquist HB, et al. Multifocal multi-site Warthin tumour [J]. *Eur Arch Otorhinolaryngol*, 2008, 265(12): 1573 – 1575.
- [16] Ory M, Eran A. Synchronous parotid and nasopharyngeal Warthin tumor [J]. *Head Neck*, 2016, 38(3): 71 – 72.
- [17] Güçlü O, Murat A, Karatağ O, et al. Synchronized Warthin's tumor in bilateral parotid gland and nasopharynx [J]. *J Ear Nose Throat*, 2012, 22(4): 236 – 240.
- [18] Low WK, Ng SB. Synchronous parotid and nasopharyngeal Warthin's tumors: first report of a case [J]. *Ear, Nose Throat J*, 2002, 81(12): 839 – 841.
- [19] Pelucchi S, Bianchini C, Ciorba A, et al. Simultaneous nasopharyngeal and parotid gland Warthin's tumour: a case report [J]. *Acta Otorhinolaryngol Ital*, 2015, 35(2): 129 – 131.
- [20] 何亚平,何愿真. 鼻咽部腺淋巴瘤 1 例 [J]. *临床耳鼻咽喉头颈外科杂志*, 2011, 25(22): 1051 – 1051.
- [21] von Laffert, M Arsenic, R Olze H, et al. Nasopharyngeal space-occupying lesion with middle ear effusion. Malignant or benign? [J]. *Der Pathol*, 2014, 35(4): 379 – 382.
- [22] Valstar MH, de Bakker BS, Steenbakkers RJHM, et al. The tubarial salivary glands: A potential new organ at risk for radiotherapy [J]. *Radiother Oncol*, 2021, 154: 292 – 298.
- [23] Iwanaga J, Ibaragi S, Nakano K, et al. No convincing evidence for the presence of tubarial salivary glands: A letter to the editor regarding "The tubarial salivary glands: A potential new organ at risk for radiotherapy" [J]. *Radiother Oncol*, 2021, 154: 321 – 322.

(收稿日期: 2021 – 02 – 26)

本文引用格式:朱杭军,刘洋君,刘赞. 鼻咽部 Warthin 瘤 1 例报道并文献复习[J]. *中国耳鼻咽喉颅底外科杂志*, 2022, 28(1): 109 – 111. DOI: 10. 11798/j. issn. 1007 – 1520. 202221071

Cite this article as: ZHU Hangjun, LIU Yangjun, LIU Yun. Warthin's tumor of the nasopharynx: a case report and literature review [J]. *Chin J Otorhinolaryngol Skull Base Surg*, 2022, 28(1): 109 – 111. DOI: 10. 11798/j. issn. 1007 – 1520. 202221071